

Brugada Sendromunda Ablasyon

Dr.Erkan BAYSAL

SBÜ Gazi Yaşargil SUAM

2022

Circulation: Arrhythmia and Electrophysiology

EDITORIAL

Endocardial Ablation Approach for Brugada Syndrome



An Important First Step or a Quixotic Quest

Risk stratification, prevention of SCD and treatment of VA		
ICD implantation is recommended in patients with BrS who: (a) Are survivors of an aborted CA and/or (b) Have documented spontaneous sustained VT. ^{980,990–992}	I	C
ICD implantation should be considered in patients with type 1 Brugada pattern and an arrhythmic syncope. ^{990,992,996}	IIa	C
Implantation of a loop recorder should be considered in BrS patients with an unexplained syncope. ^{997,999}	IIa	C
Quinidine should be considered in patients with BrS who qualify for an ICD but have a contraindication, decline, or have recurrent ICD shocks. ^{922,1006,1007}	IIa	C
Isoproterenol infusion should be considered in BrS patients suffering electrical storm. ¹⁰⁰⁸	IIa	C
Catheter ablation of triggering PVCs and/or RVOT epicardial substrate should be considered in BrS patients with recurrent appropriate ICD shocks refractory to drug therapy. ^{1010–1015}	IIa	C
PES may be considered in asymptomatic patients with a spontaneous type I BrS ECG. ¹⁵⁵	IIb	B
ICD implantation may be considered in selected asymptomatic BrS patients with inducible VF during PES using up to 2 extra stimuli. ¹⁵⁵	IIb	C

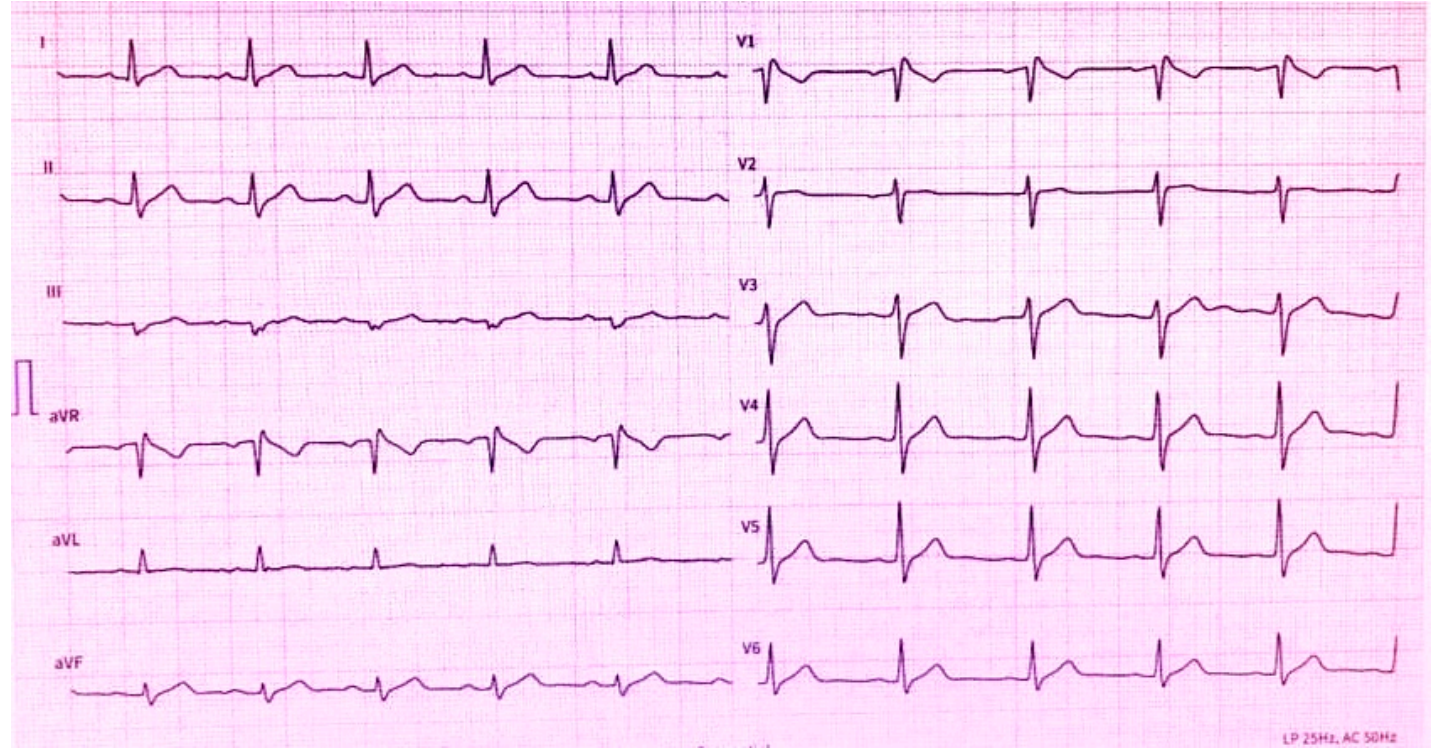
OLGU

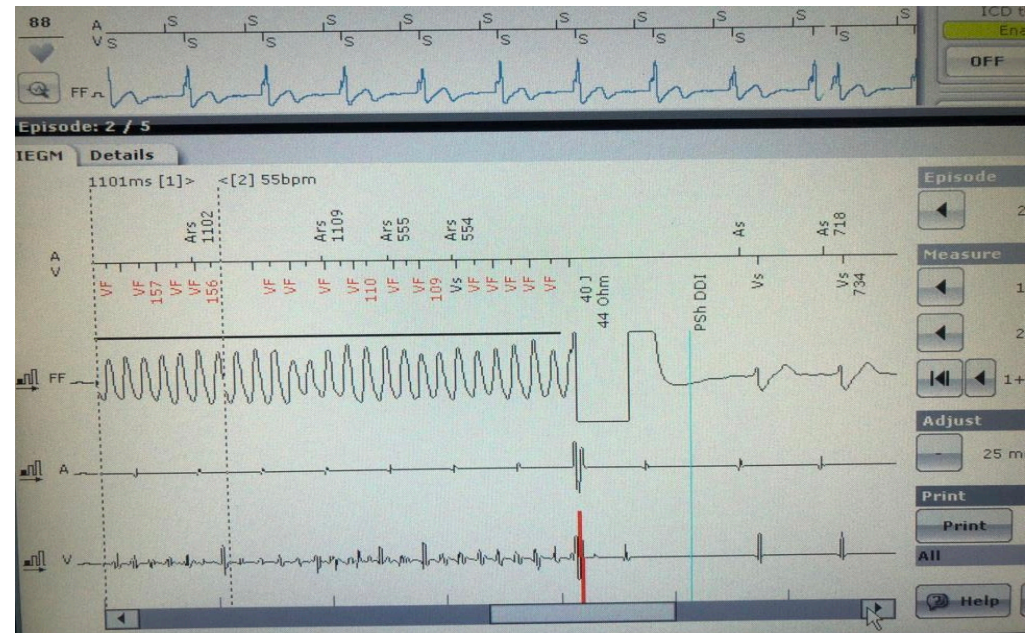
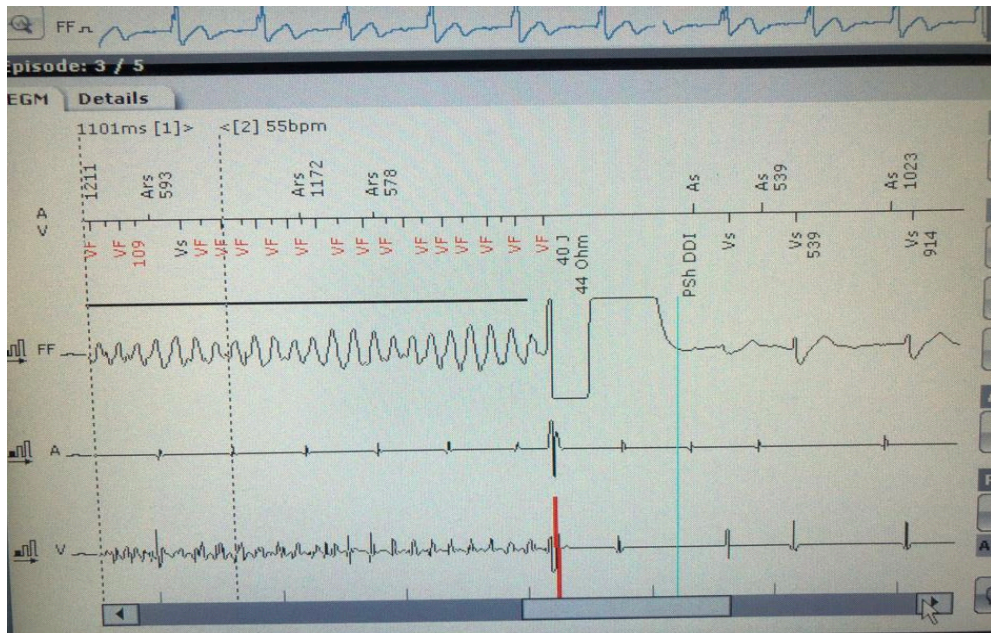
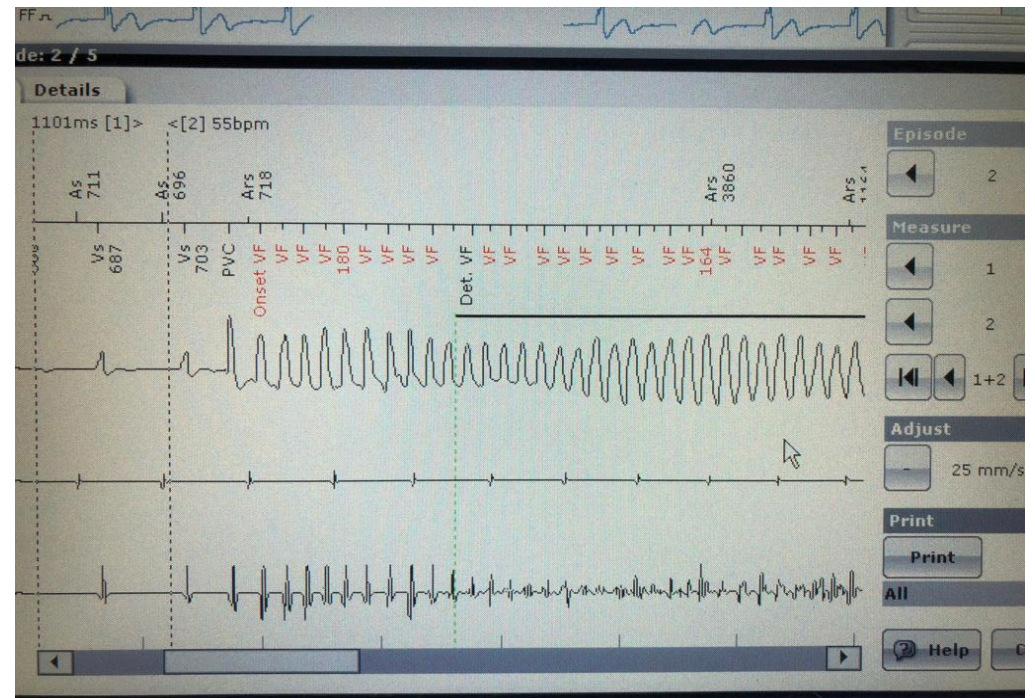
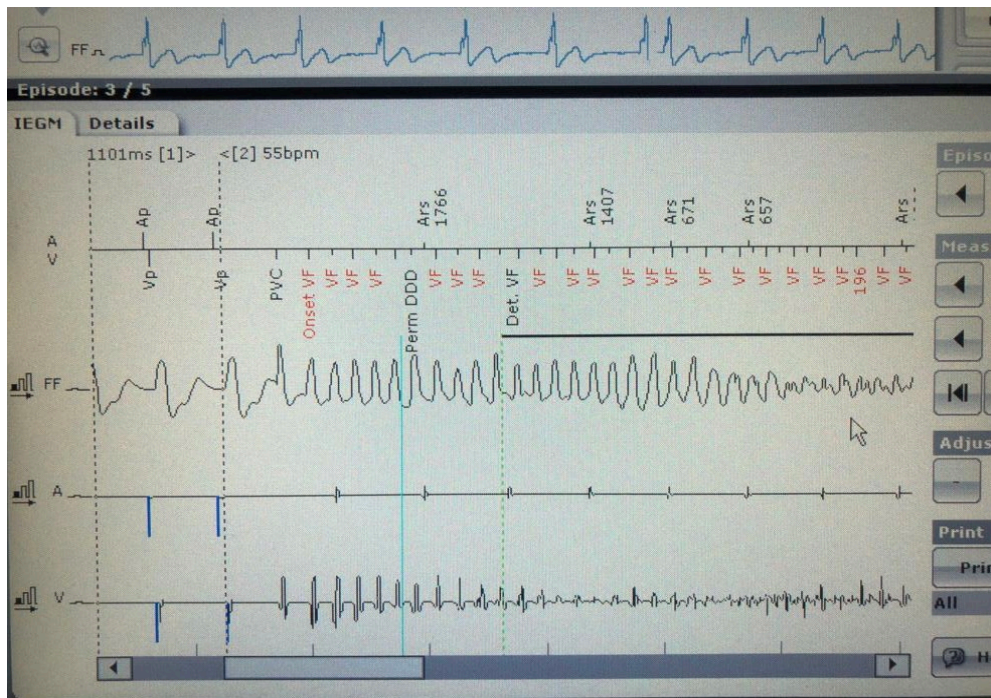35 y erkek hasta

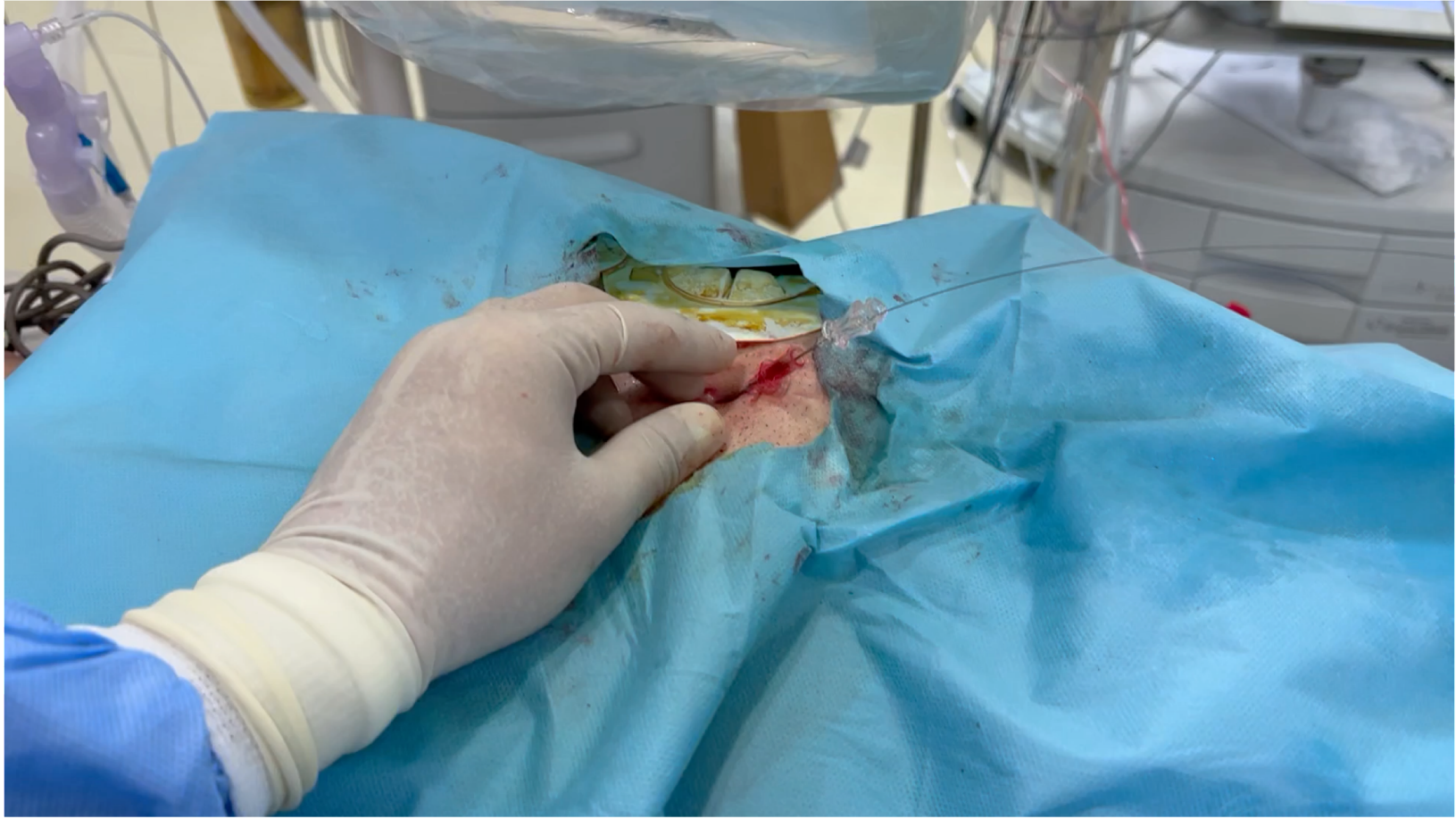3 yıl önce indeks olay

ICD implantasyonu


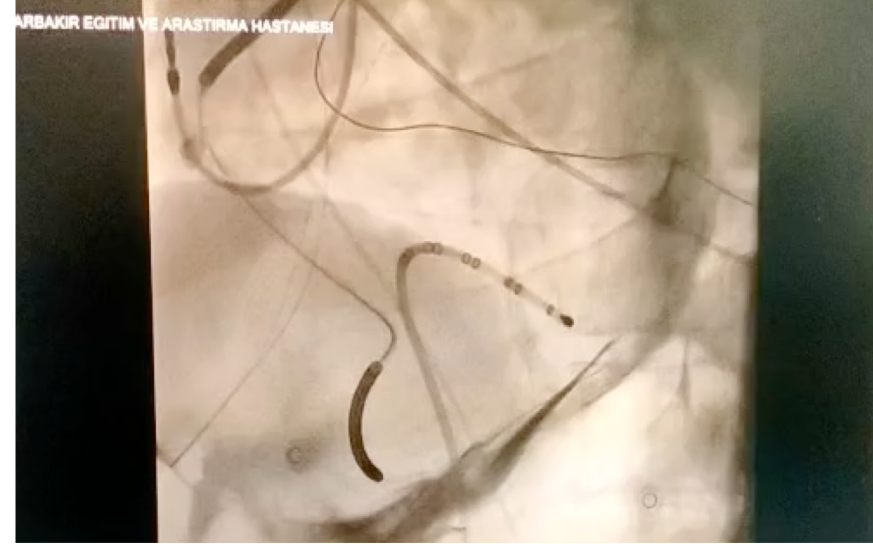
Mükerrer ICD şoklaması





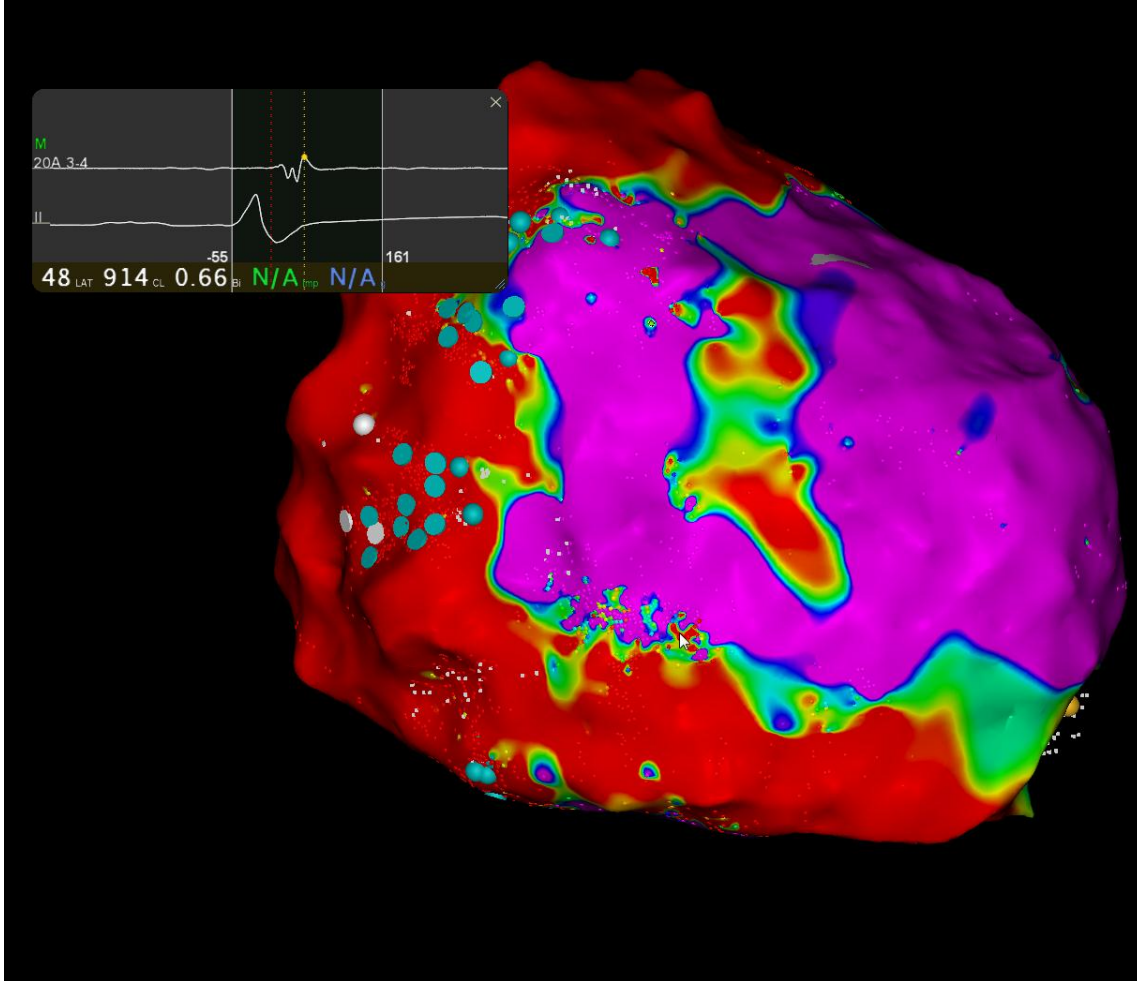


Skopi

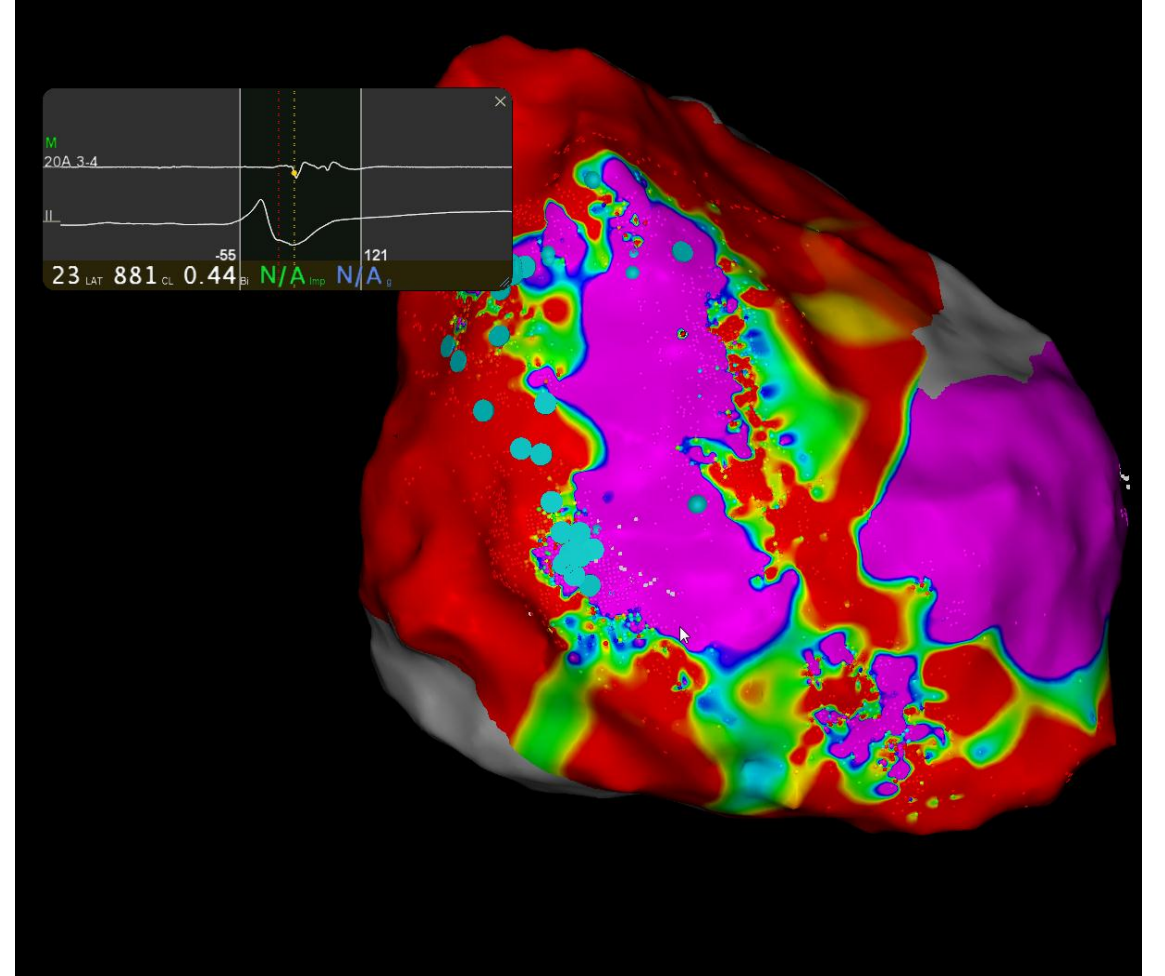


Voltaj Haritalama

Ajmalin Öncesi

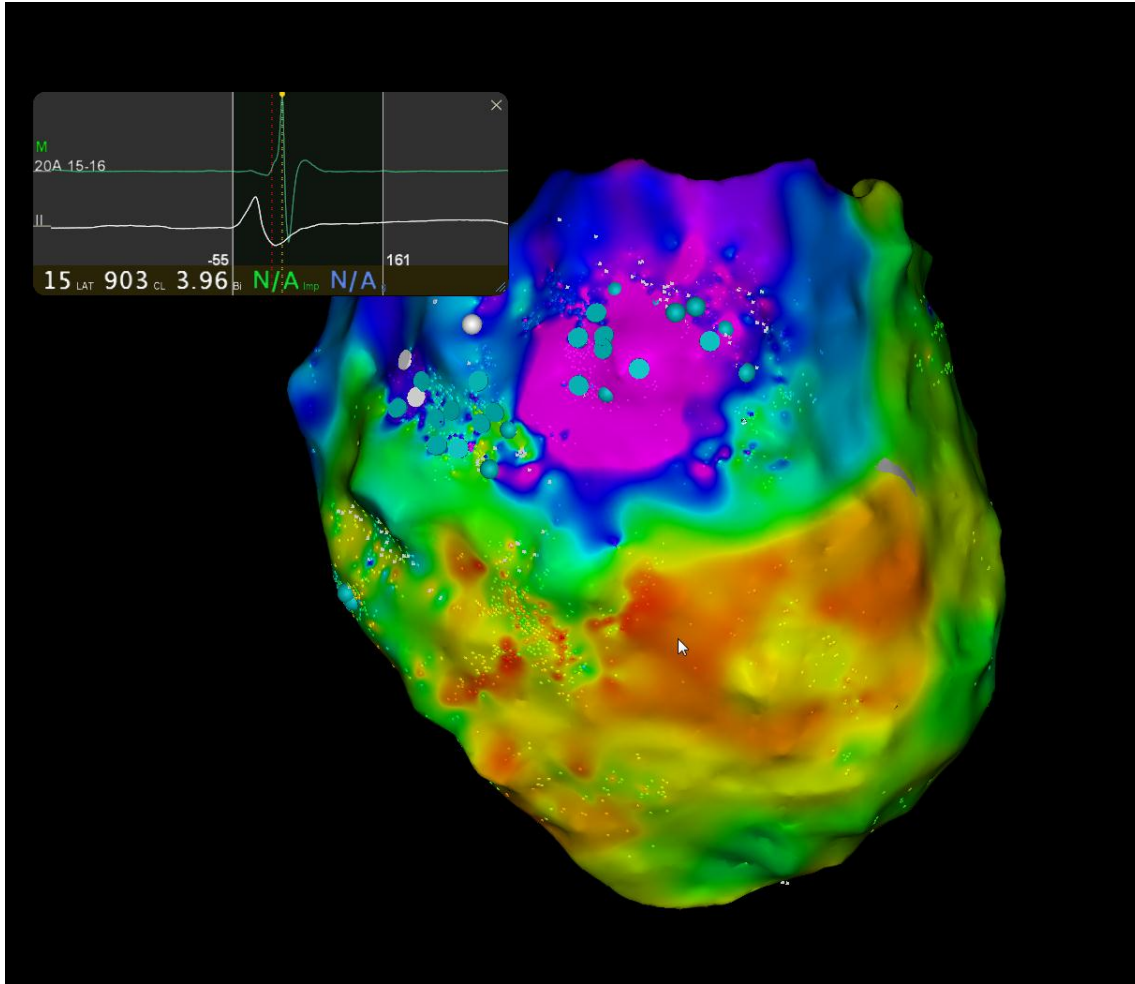


Ajmalin Sonrası

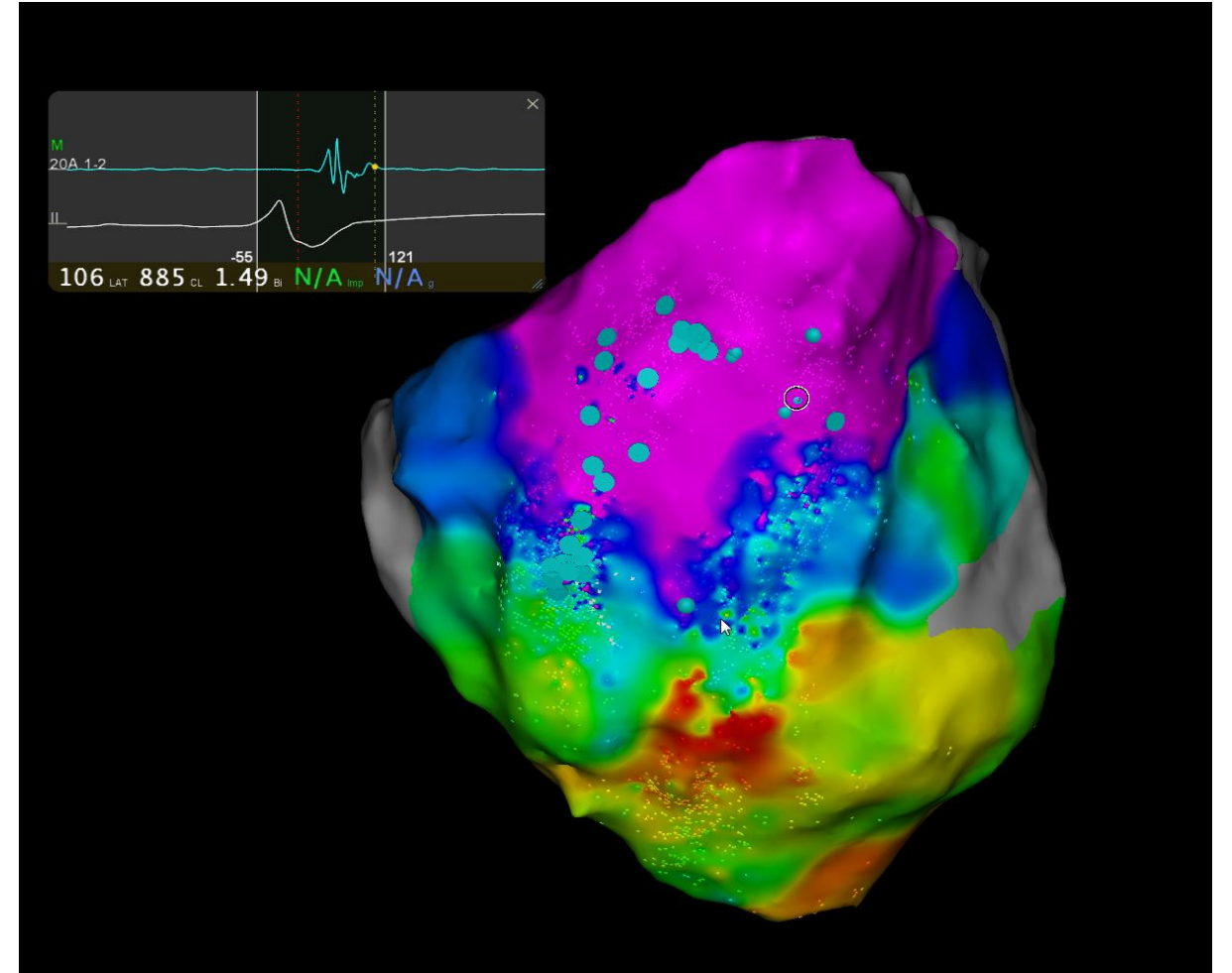


LAT

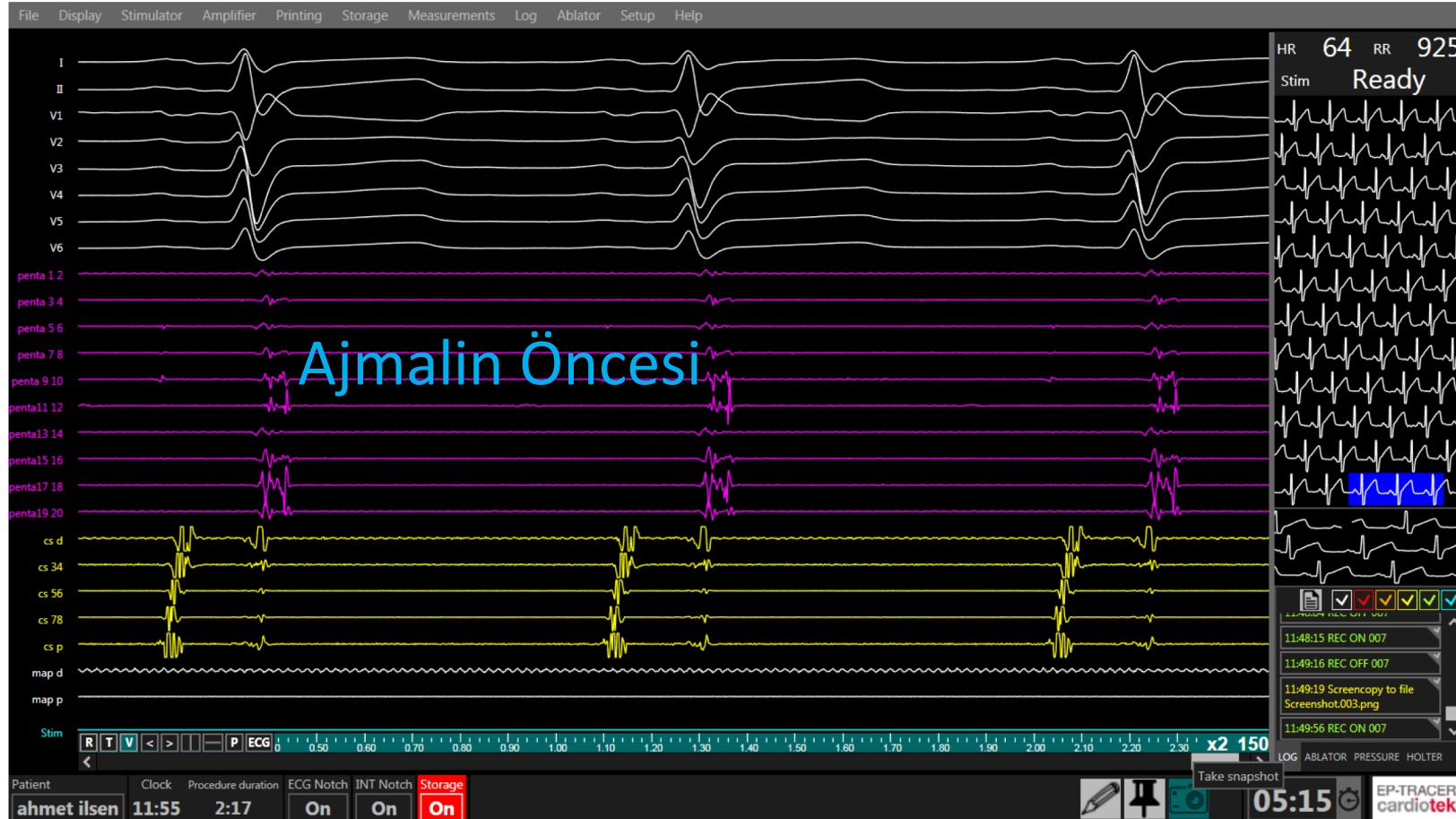
Ajmalin Öncesi



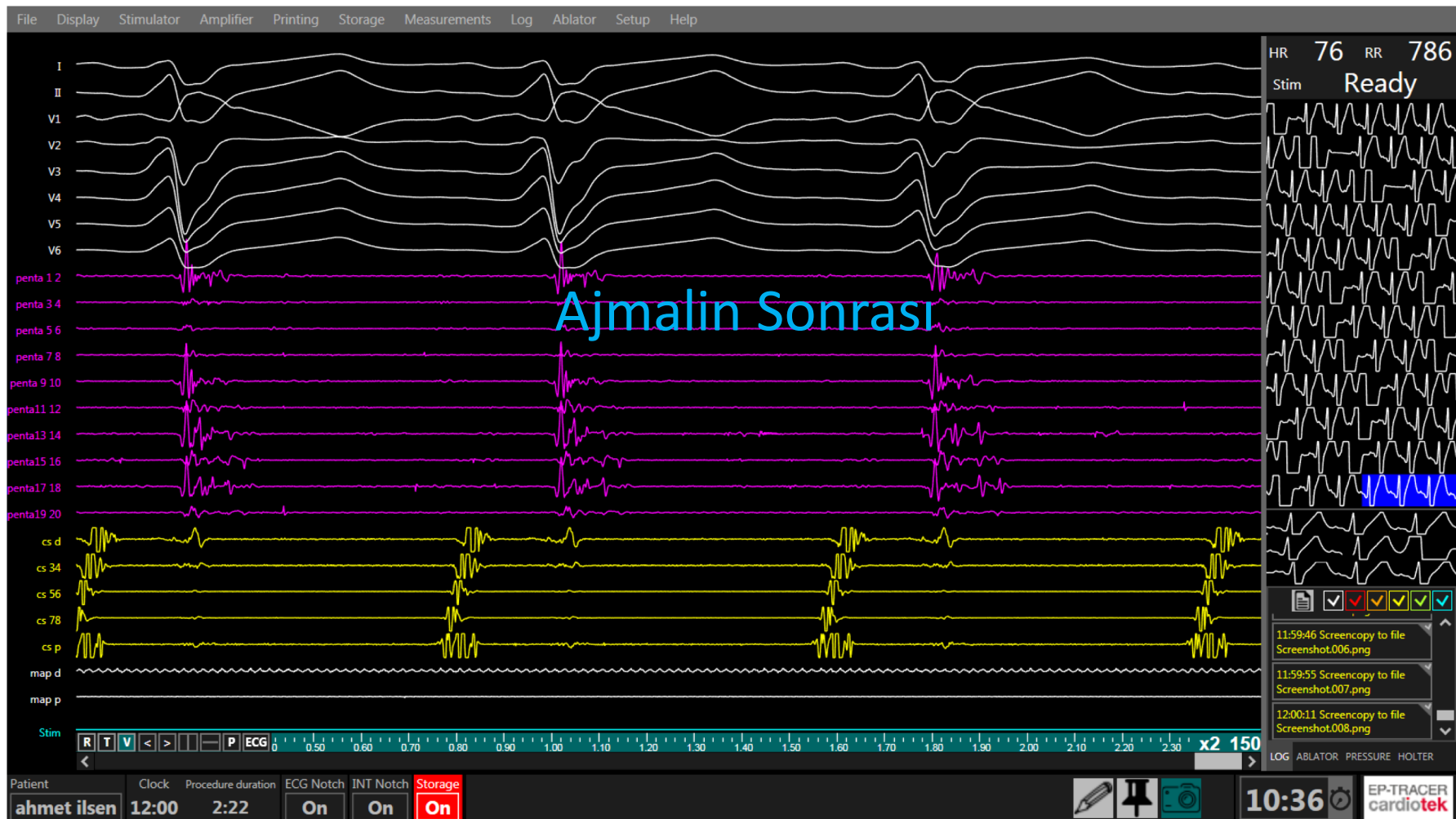
Ajmalin Sonrası



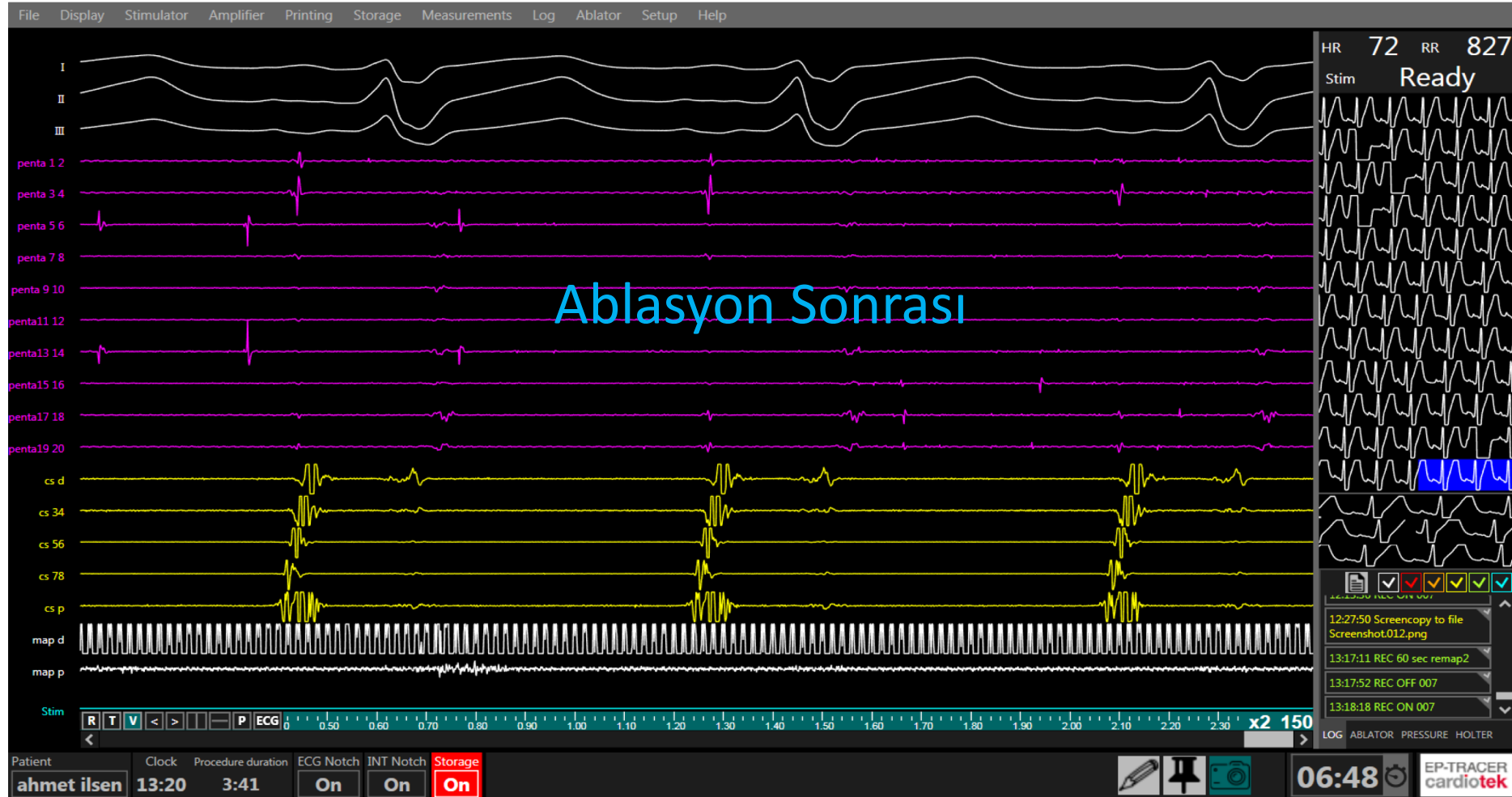
Pentaray EGM



Pentaray EGM




Pentaray EGM

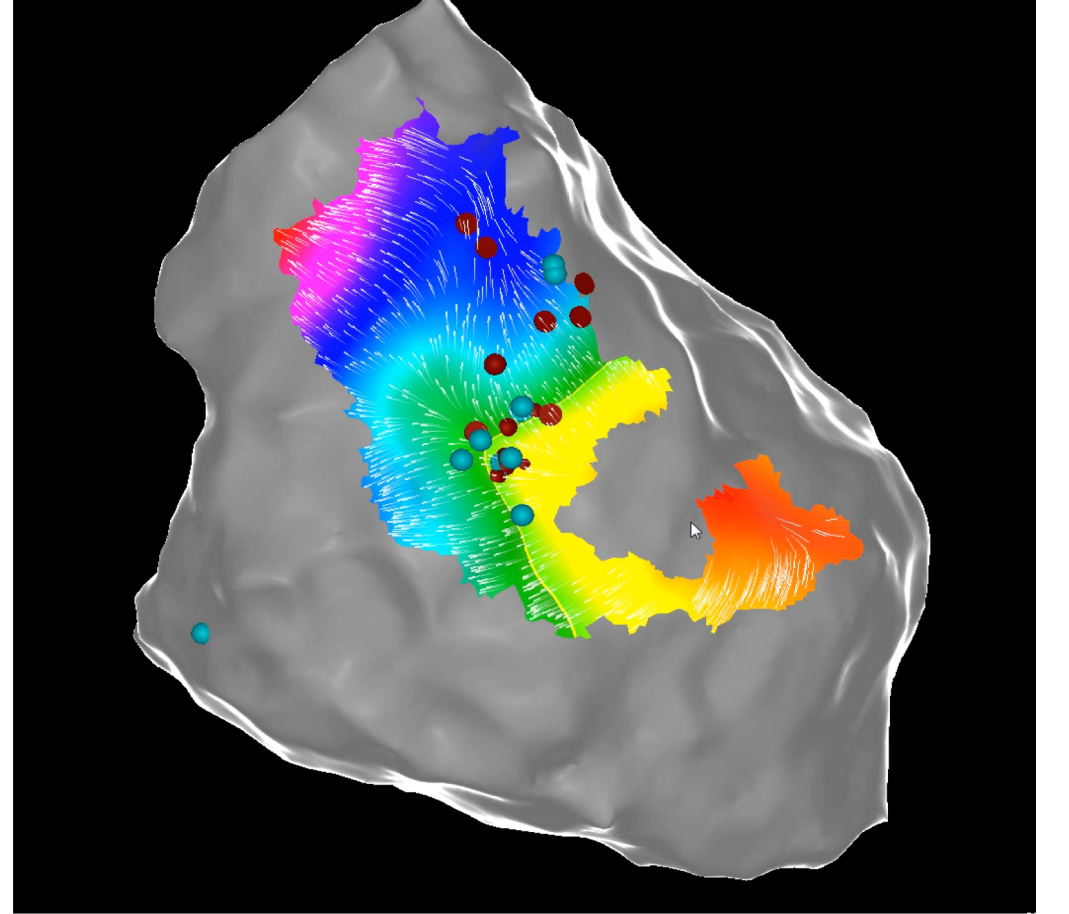


Koherent

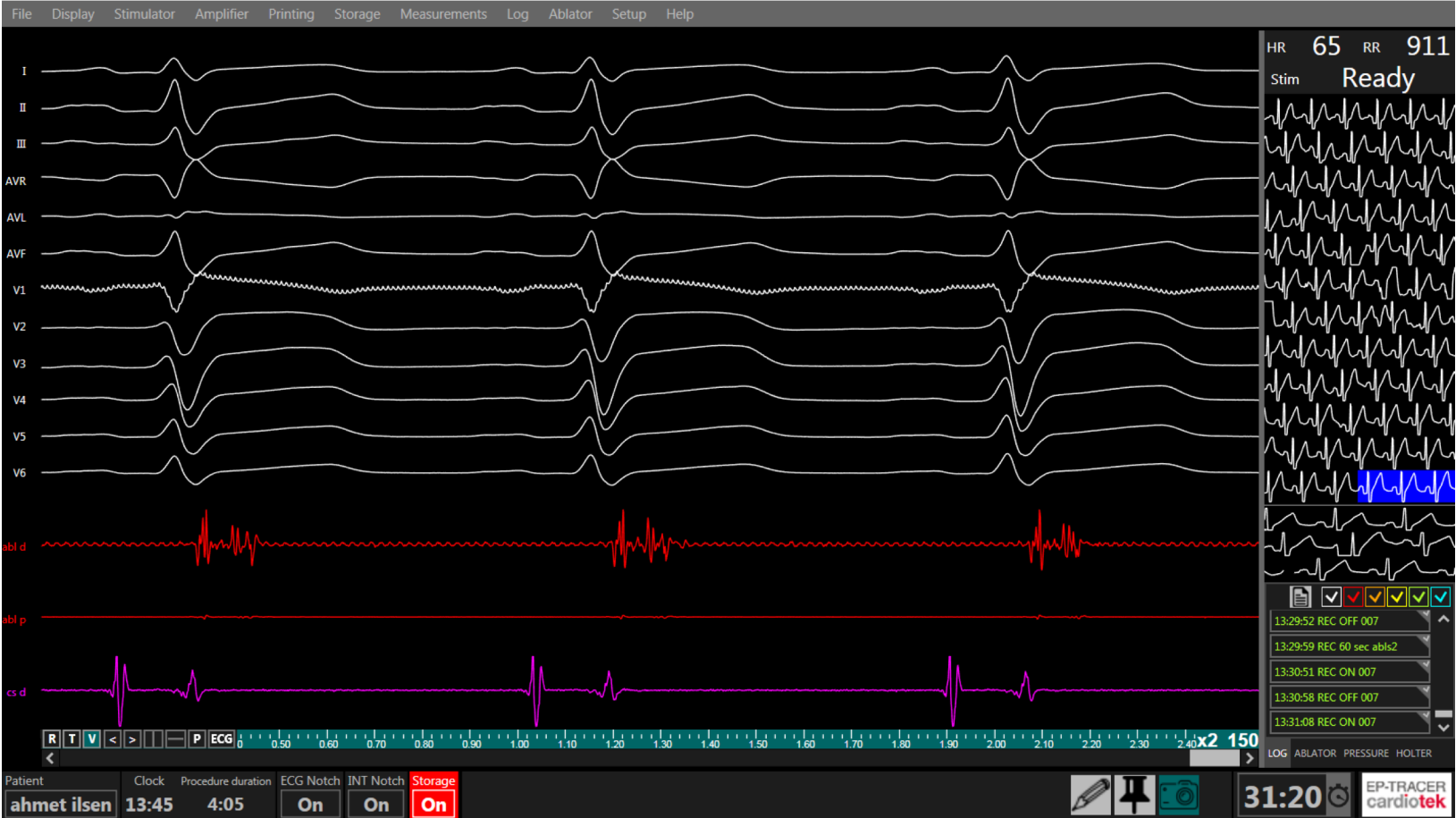Ablasyon Öncesi



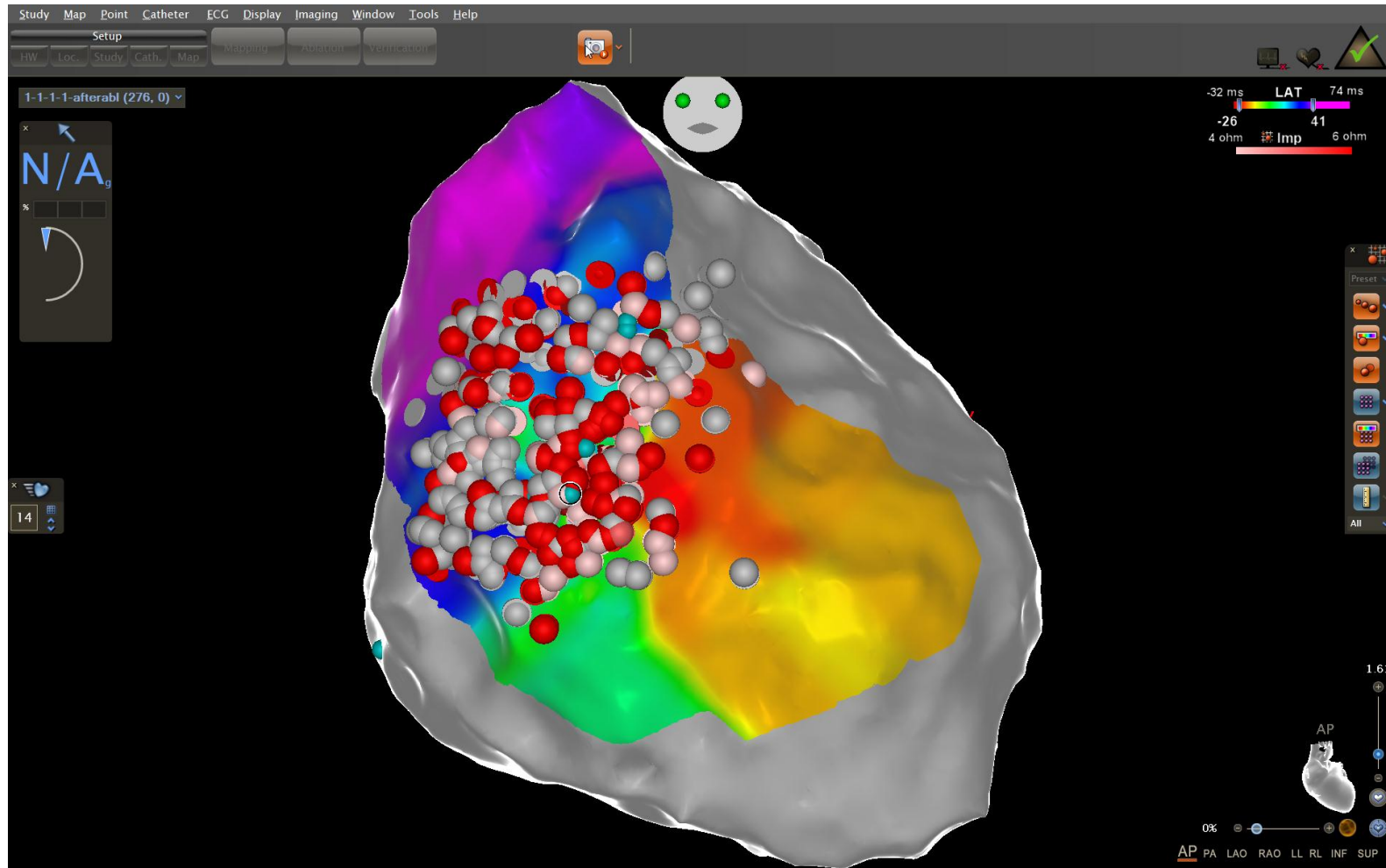
Ablasyon Sonrası



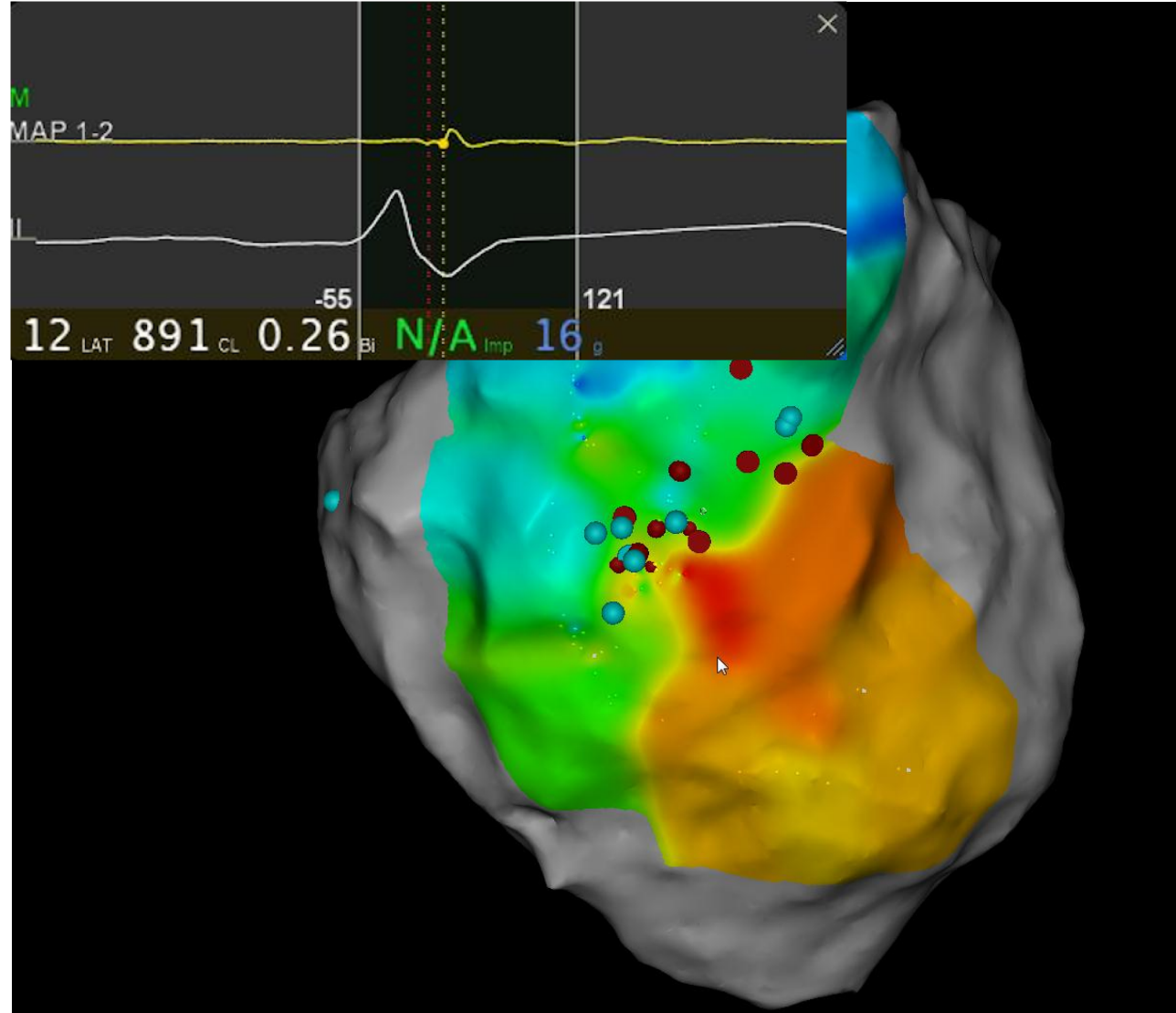
Ablasyon EGM

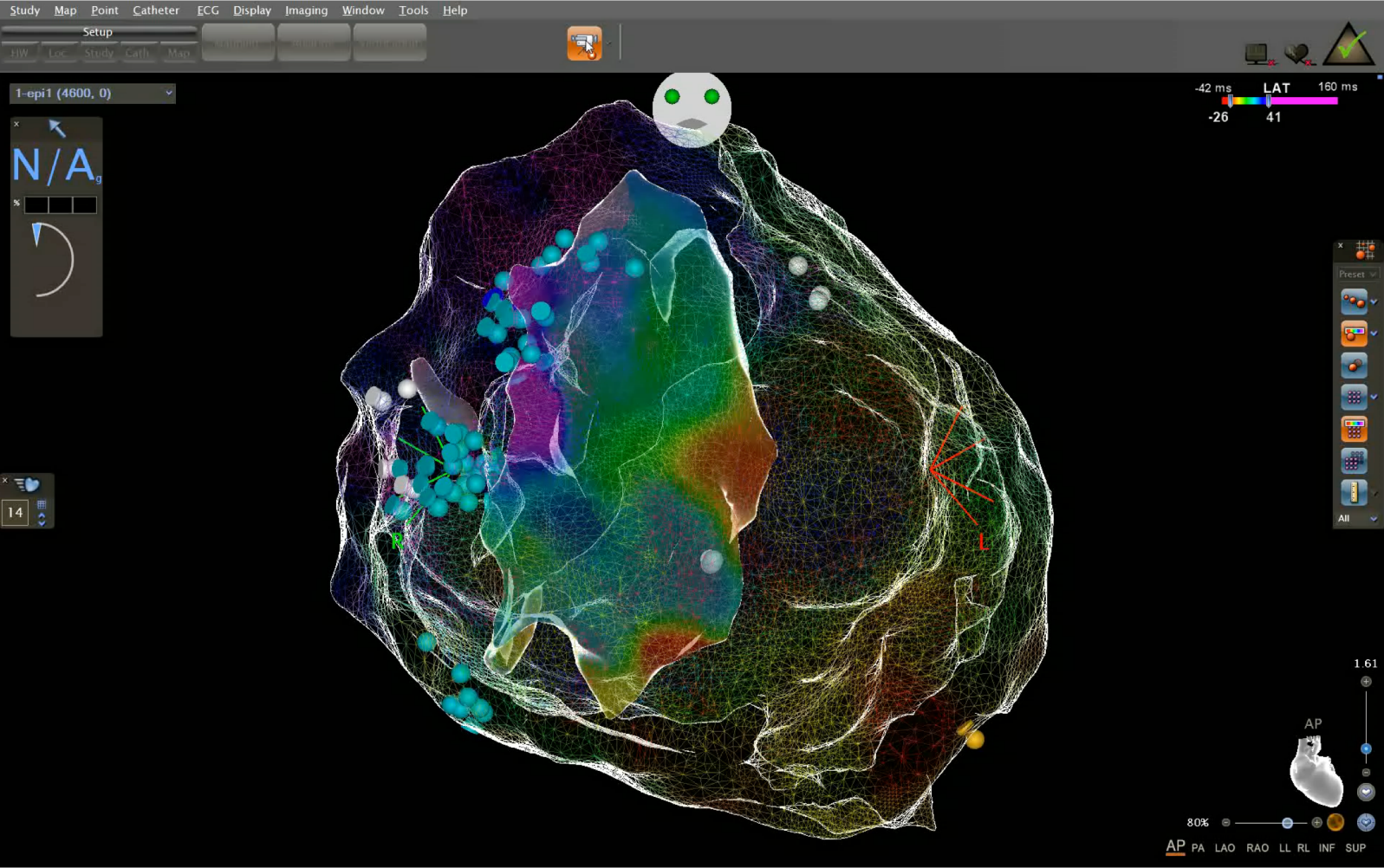


Ablasyon Noktaları



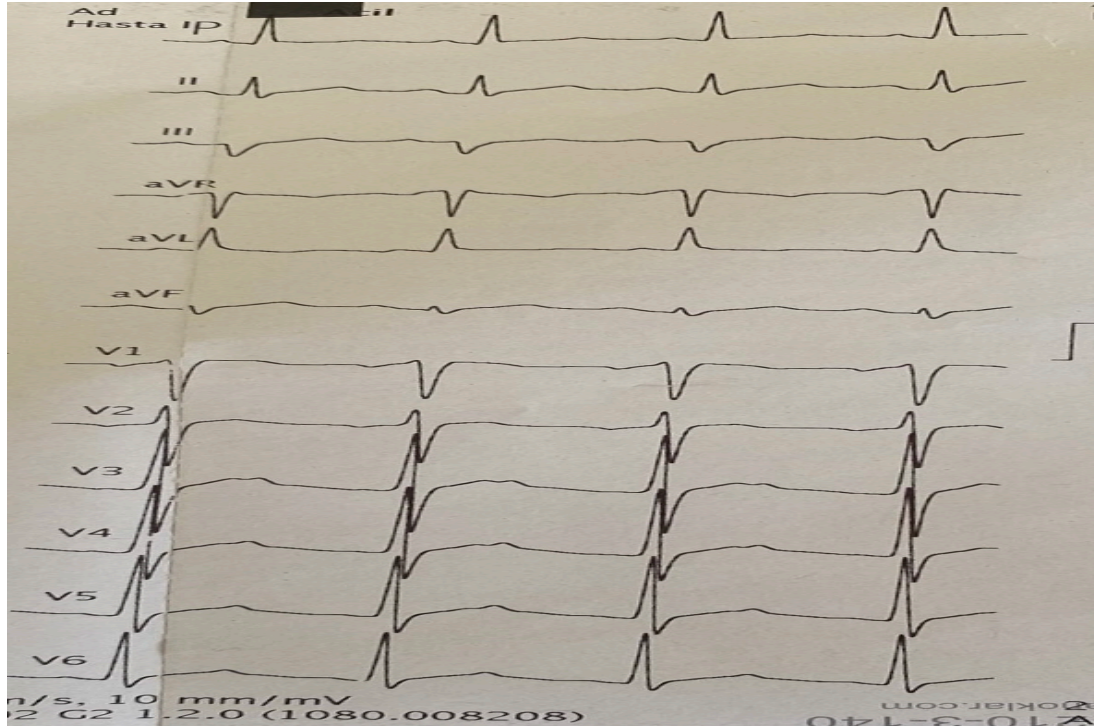
Ablasyon Sonrası



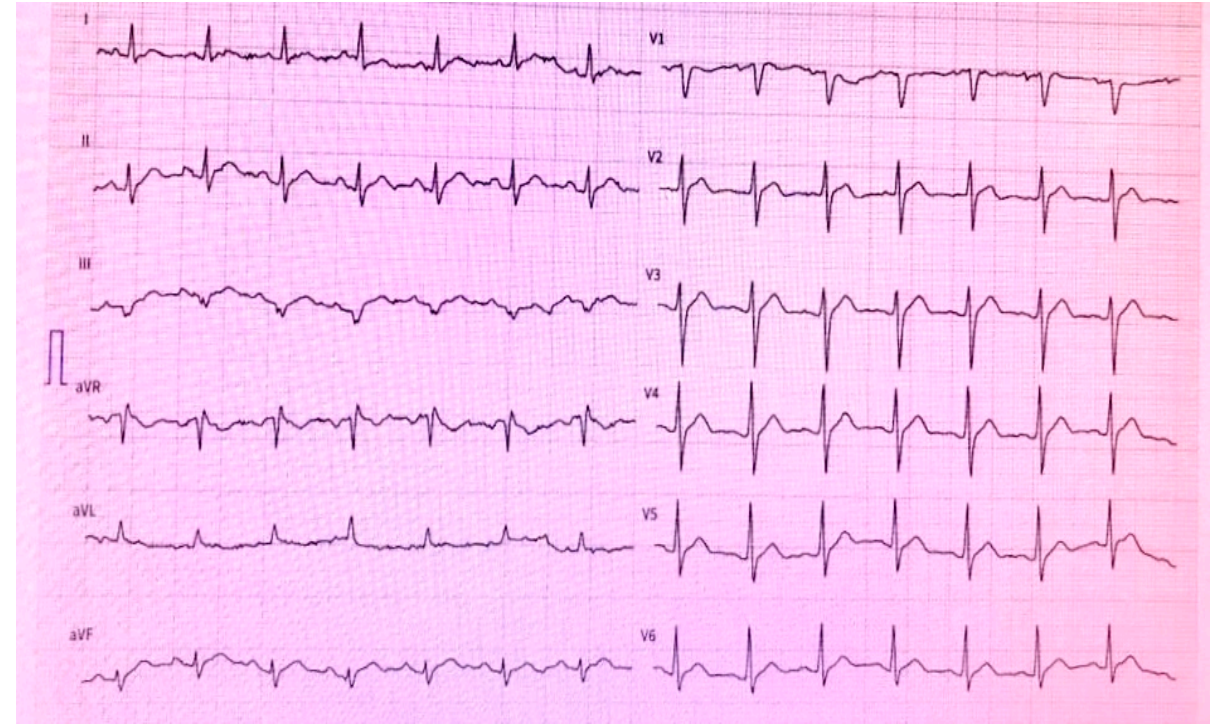


EKG

İşlem Sonrası



6. Ay Kontrol



Diğer Aritmiler

- PVI
- Aksesuar yol ablasyonu
- AVNRT
- AFL

Teşekkürler

